

## **Title: Intrauterine fetal demise in one twin in MCDA twin gestation** **Termination or continuation of pregnancy-A clinical Dilemma-Case Report**



### INTRODUCTION

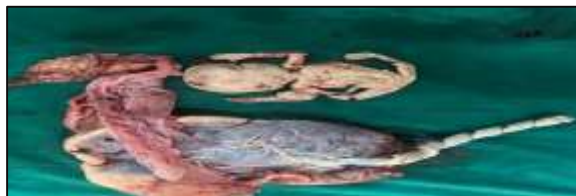
- Intrauterine demise occurs in 5% of all twin pregnancies. The etiology is unknown in the majority of cases. Single intrauterine demise may cause severe outcomes for the surviving fetus, especially in monochorionic twin pregnancies. Complications such as cerebral impairment, preterm labor and related sequelae, and subsequent death of the surviving fetus may occur in these cases.

### AIMS / OBJECTIVES

To report a case of MCDA twin gestation with intrauterine fetal demise of one twin at 25 weeks 3 days and pregnancy continued till term

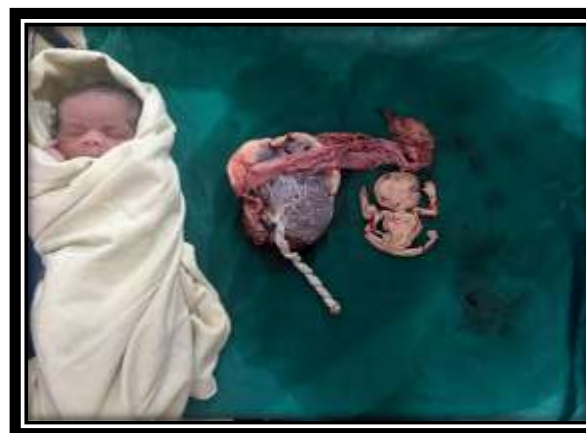### MATERIALS / METHODS

24 year old G2P1L1 with 27 weeks 3 days with MCDA twin gestation with previous vaginal delivery came for antenatal checkup with scan report showing intrauterine fetal demise of one twin. Scan report showed Twin intrauterine gestation with Twin A live 25 weeks 1 day with normal Doppler parameters and twin B 16 weeks 5 days with no cardiac activity. Repeat scan after 1 week also done with Twin A live with normal Doppler parameters. Patient was monitored serially with USG and coagulation profile which was repeated every 3 days with no derangement.. She was advised to come weekly for antenatal checkup.



### RESULTS

- She was then admitted at 35 weeks 2 days in early labor and Emergency CD done I/v/o NRNST and extracted live male baby weighing 2040g and twin B fetus papyraceus. Placenta and membranes sent for HPE.
- Follow up done and Twin A has attained all milestones and has normal neurological development.



### DISCUSSION

Although MCDA twin pregnancy with single intrauterine fetal demise has poor outcome, regular monitoring with serial USG and follow up pregnancy can be continued until the Doppler parameters are normal and coagulation profile of the mother is within normal limits.

### CONCLUSION

Twin pregnancy itself comes with its set of complications. Single intrauterine fetal demise in MCDA twin gestation needs close monitoring and regular follow up and multidisciplinary approach for a favorable outcome of both the mother and fetus. Authors declare that there are no conflict of interest.

### REFERENCE

Farah N et al Prospective risk of fetal death in uncomplicated monochorionic twins.. 2012 Mar;91(3):382-5. doi: 10.1111/j.1600-0412.2011.01288